

5th Annual UMEM Residency ECG Competition

April 26, 2017



Name: _____

What program are you in? (circle one)

EM

EM/Peds

EM/IM

EM/IM/CC

What is your PG year? (1-5) _____

Differentials:

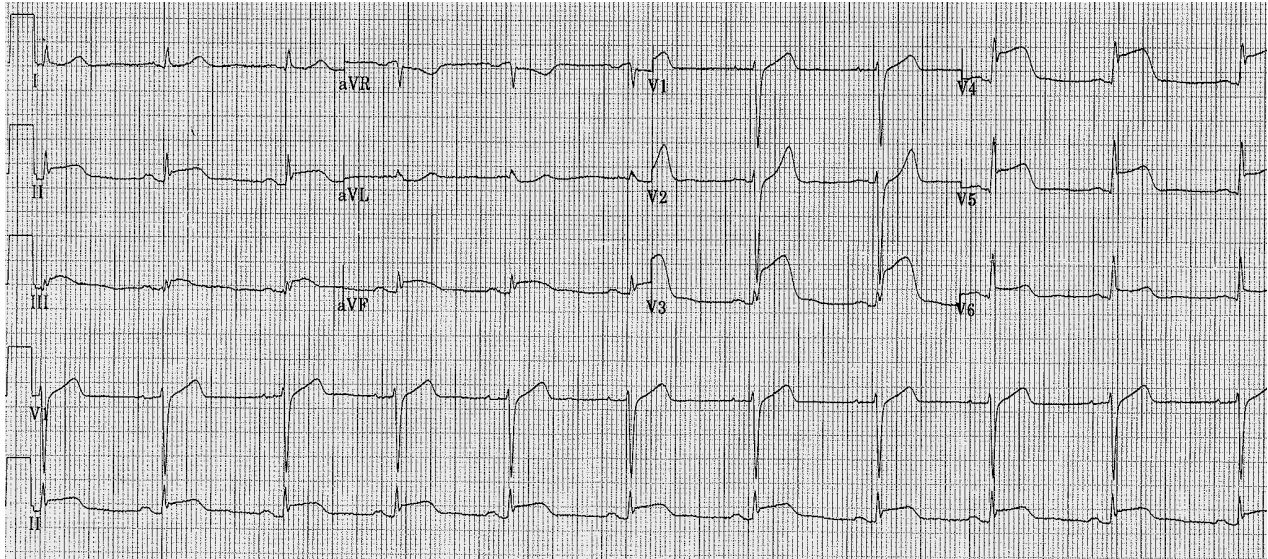
1. List up to 16 causes of STE (1 point for every 3 you list; bonus point for all 16; max 6 points)

2. Name 6 causes of STE in lead aVR that are NOT related to acute coronary syndrome (i.e. not left main, triple vessel, or proximal LAD artery disease)
(max 3 points)

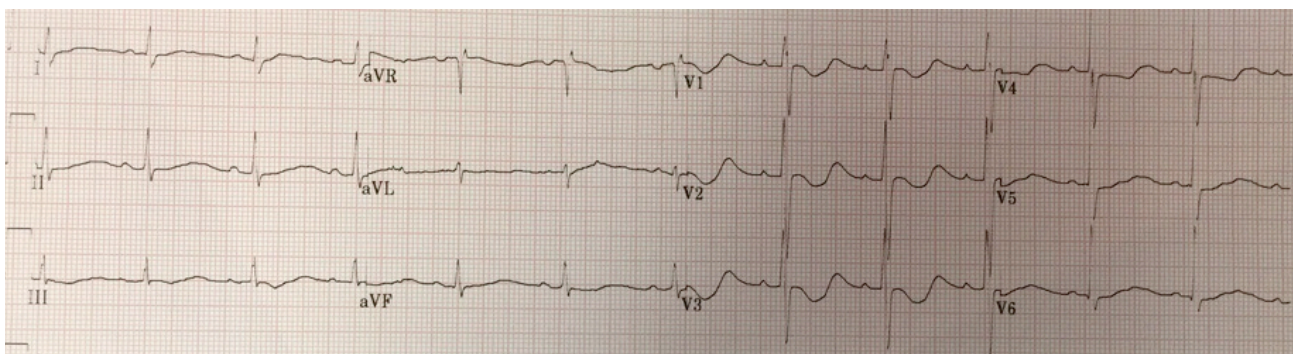
3. Name 4 ECG signs of right heart strain that might be found on the ECG of a patient with a massive PE. Note that sinus tachycardia is too nonspecific...don't bother listing that!
(max 2 points)

4. Name causes for a rightward axis.
(1 point for every 3 you list, max 3 points)

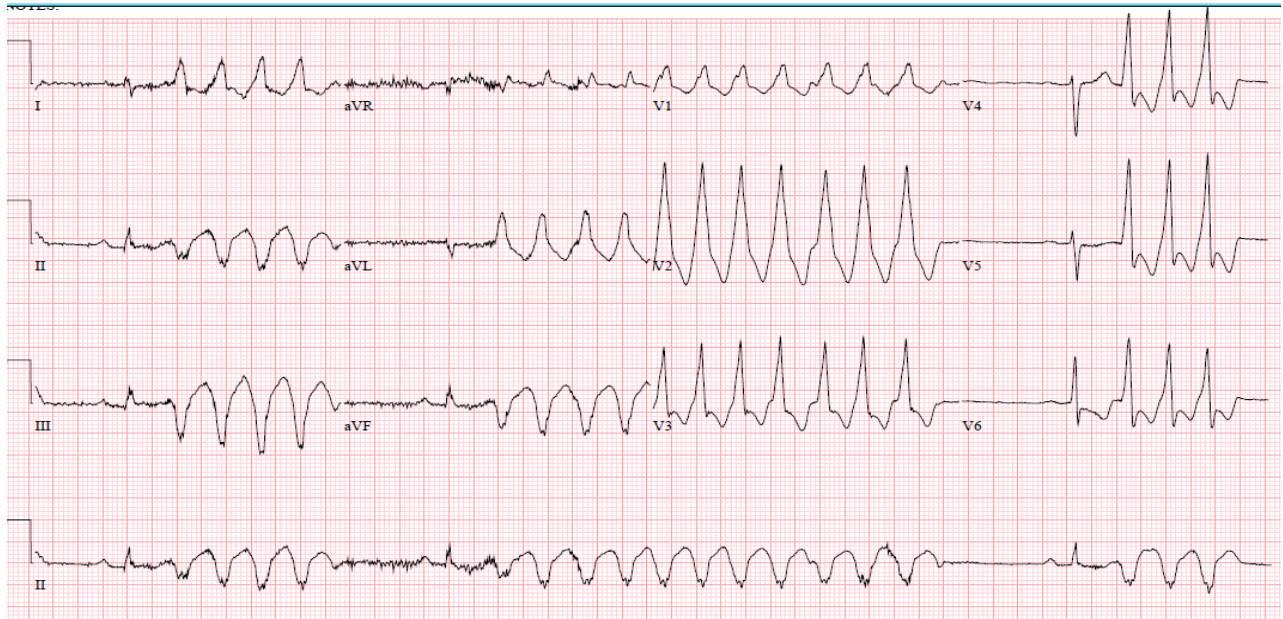
5. A 38 yo M presents with sharp chest pain and the ECG shown below. In deciding between STEMI vs acute pericarditis, name 2 findings which strongly favor the correct diagnosis over the other. (2 points)



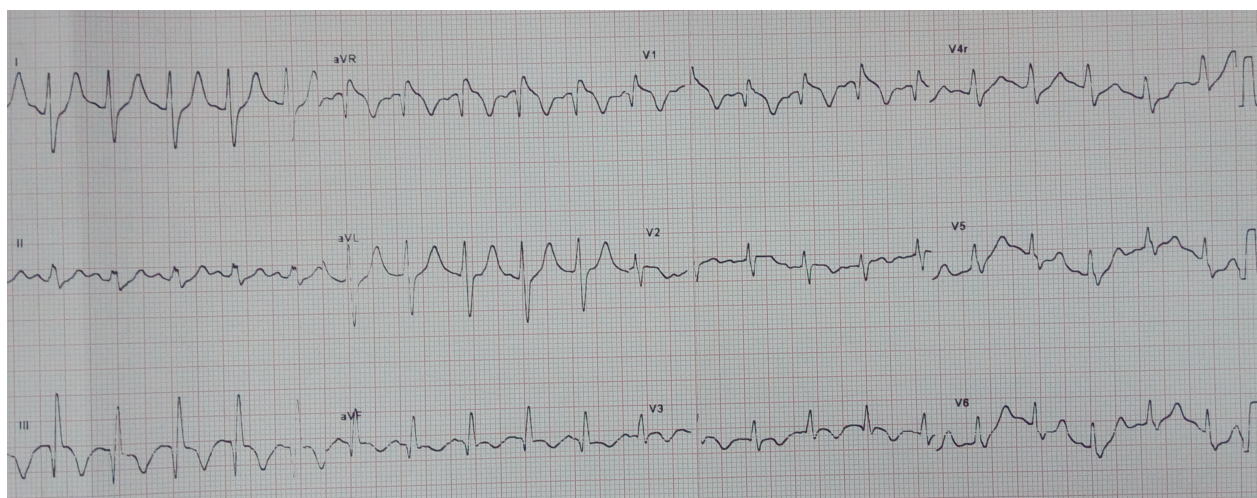
6. A 45 yo W presents feeling weak, with the ECG shown below.
What is the dx? (1 point)
Name 4 typical ECG findings associated with this diagnosis. (2 points)



7. A 62 yo M with prior history of CAD presents with palpitations. His BP is 115/60. He has no pain, minimal dyspnea, clear lungs, and normal mental status. Electrolytes are normal.
 What is the ECG diagnosis? (1 point)
 What is the DRUG of choice? (1 point)



8. A 37 yo M presents with chest pain and the ECG noted below.
 What is the diagnosis? (2 points)

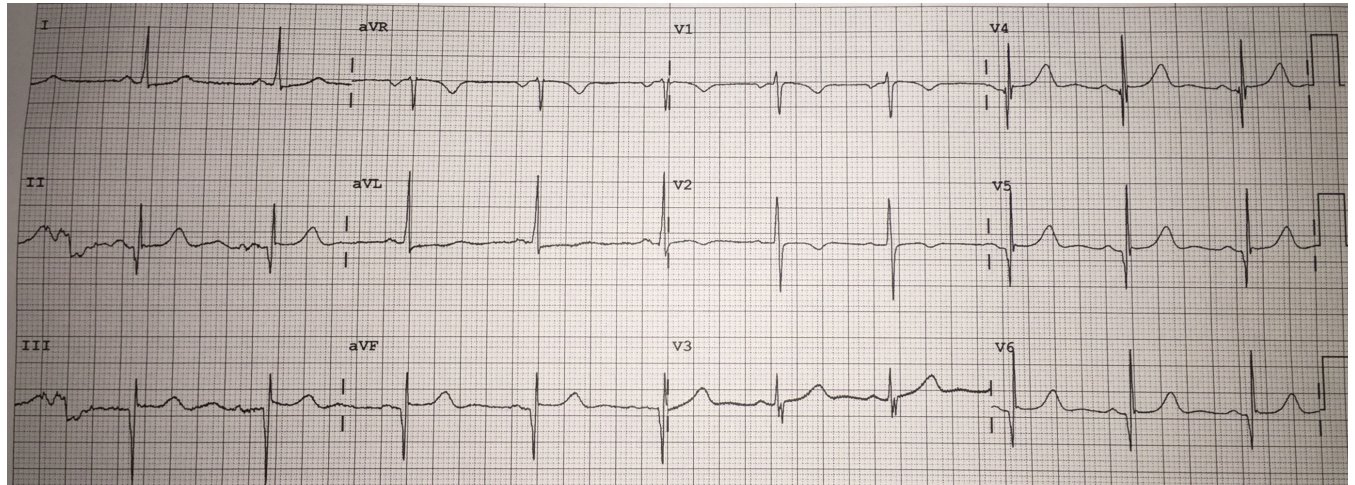


9. A 31 yo M presents after a near-syncopal episode. His ECG is shown below.

What is the diagnosis? (1 point)

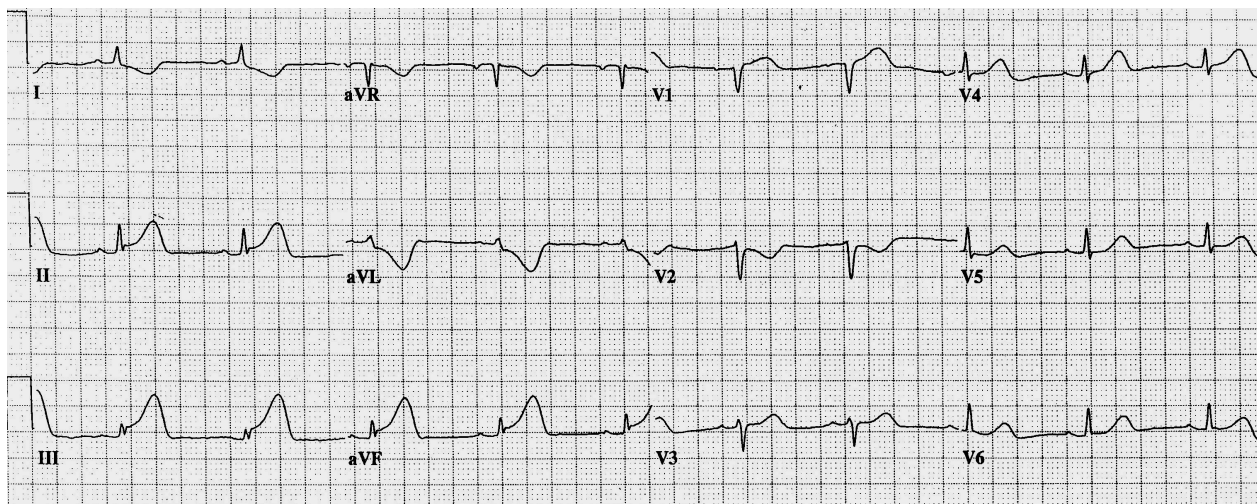
What is the diagnostic test of choice? (1 point)

The patient insists on being discharged but will followup with cardiology in 3 days. What is the optimal outpatient management until followup? (1 point)



10. A 54 yo man presents with chest pain and the ECG noted below.

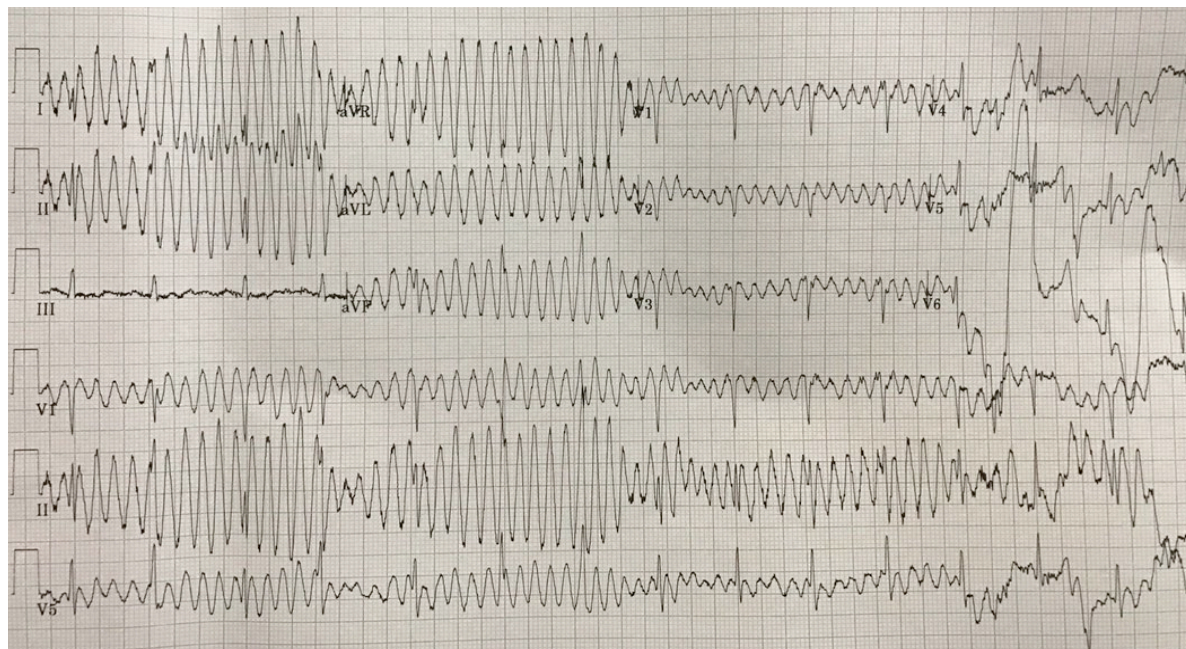
What is the FULL ECG dx? (2 points)



11. A 50 yo W presents with mild dyspnea. Nurses noted ~ 10 seconds of an unusual rhythm disturbance on the monitor and they were able to obtain a 12-lead ECG from off the monitor, noted below, from that brief period.

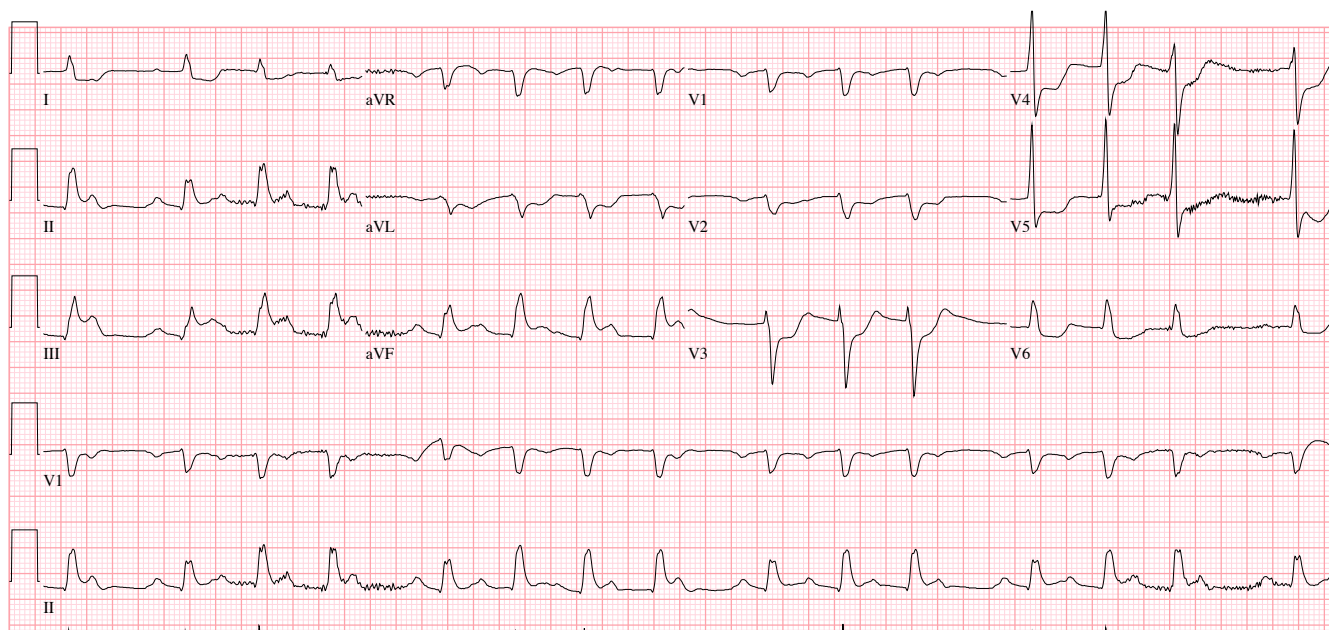
What is the diagnosis? (1 point)

What would the treatment if this finding persisted? (1 point)

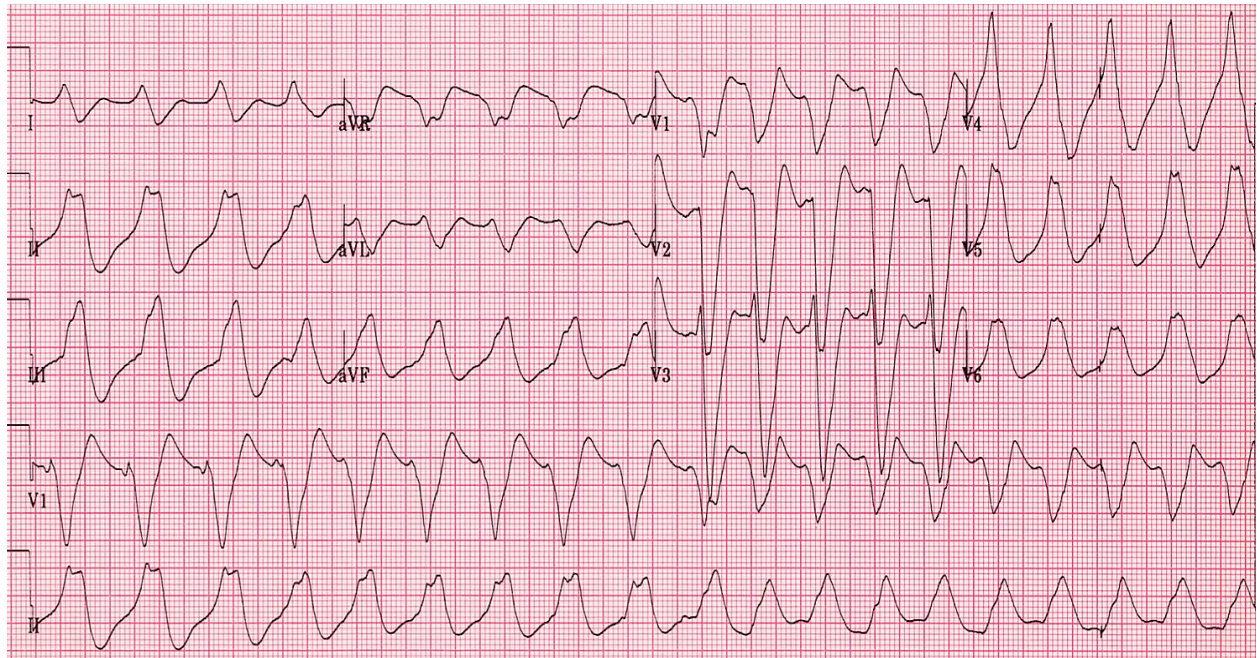


12. A 58 yo M presents with chest pain and the ECG noted below.

What is the FULL ECG diagnosis? (3 points)



13. 64 yo man presents with palpitations and lightheadedness. ECG is below.
What is the optimal treatment? (2 points)



14. A 65 yo W presents after a syncopal episode. Her ECG is below.
What is the FULL ECG diagnosis? (4 points)

