

12th Annual UMEM Residency ECG Competition

May 8, 2024



Name: _____

What program are you in? (circle one)

EM

EM/Peds

EM/IM

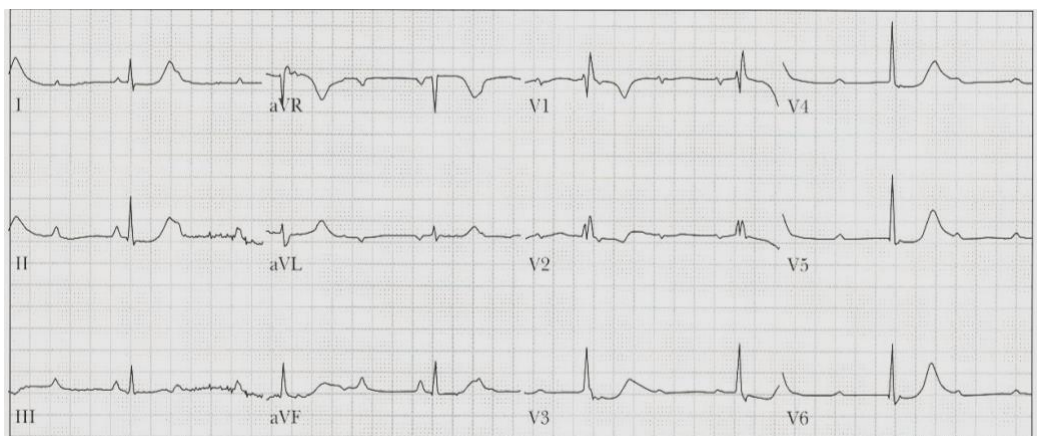
EM/IM/CC

What is your PG year? (1-5) _____

1. Please list the indications for emergent cath lab activation for presumed acute coronary occlusion/occlusion MI.
(6 points)

In some of the following questions, I'll ask you for a FULL ECG interpretation/diagnosis. Here's what I am asking for:

SAMPLE QUESTION: A 58 yo M presents with chest pain and the ECG noted below.
What is the FULL ECG diagnosis? (5 points)



Answer:

Sinus tachycardia, complete heart block, junctional escape rhythm, RBBB, diffuse ischemia

In this example, I would give you 1 point for identifying the atrial rhythm (ST), one point for identifying CHB, 1 point for identifying that there is a junctional escape, 1 point for identifying the RBBB, and one point for noting the ischemia (ST depression in multiple leads). In other words...

be complete in your interpretation!

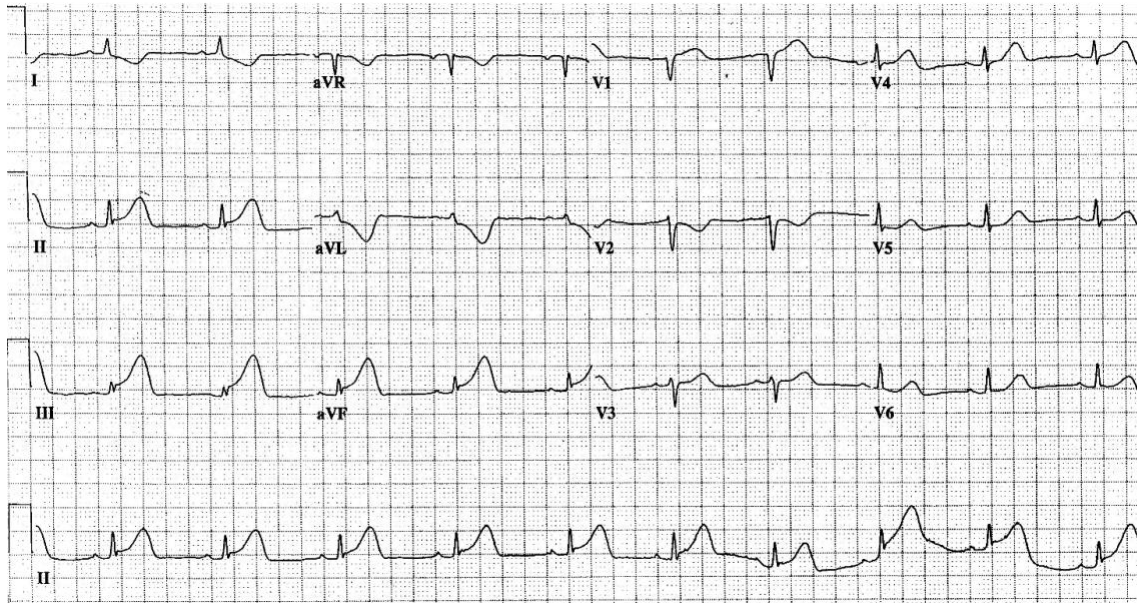
Be sure that you don't just *describe* what you see....*interpret* the ECG! For example, I don't want you to say "ST depression in ___ leads." I want you to say "diffuse ischemia."

In your interpretation, if you think there's an underlying issue, say it.

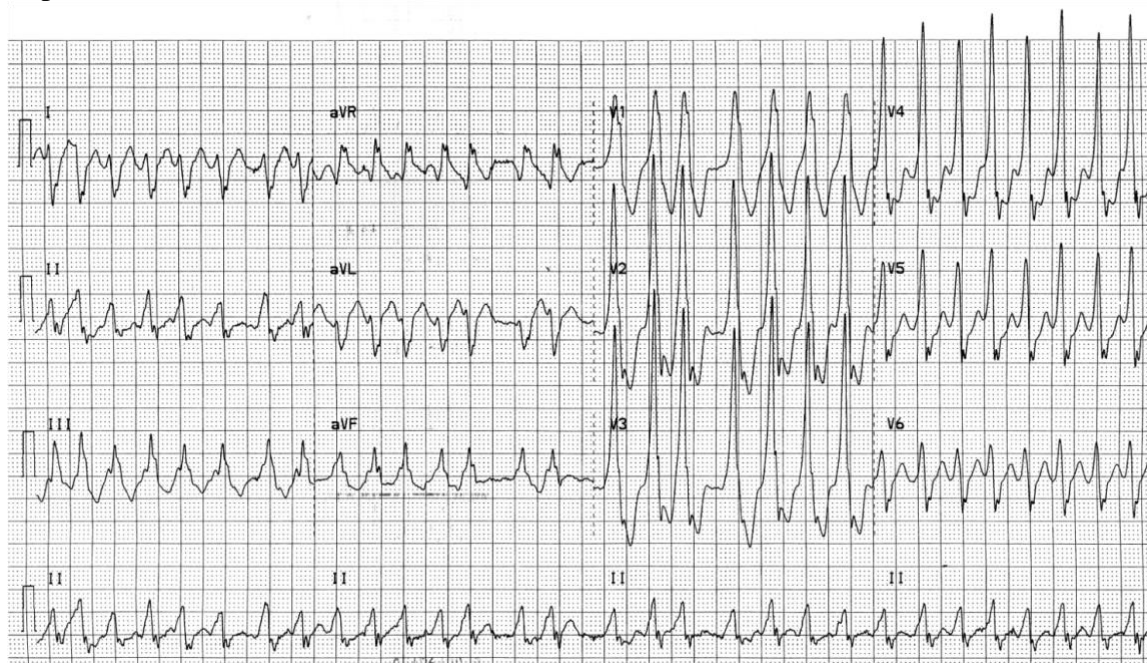For example, if you think the underlying dx is hyperK, or TCA OD, or Brugada, etc., say it.

Don't assume that points correlate with the number of things I am looking for. For example, if something is worth 3 points, that does NOT mean there are 3 things you need to list! Points are allotted based on how important I think something is.

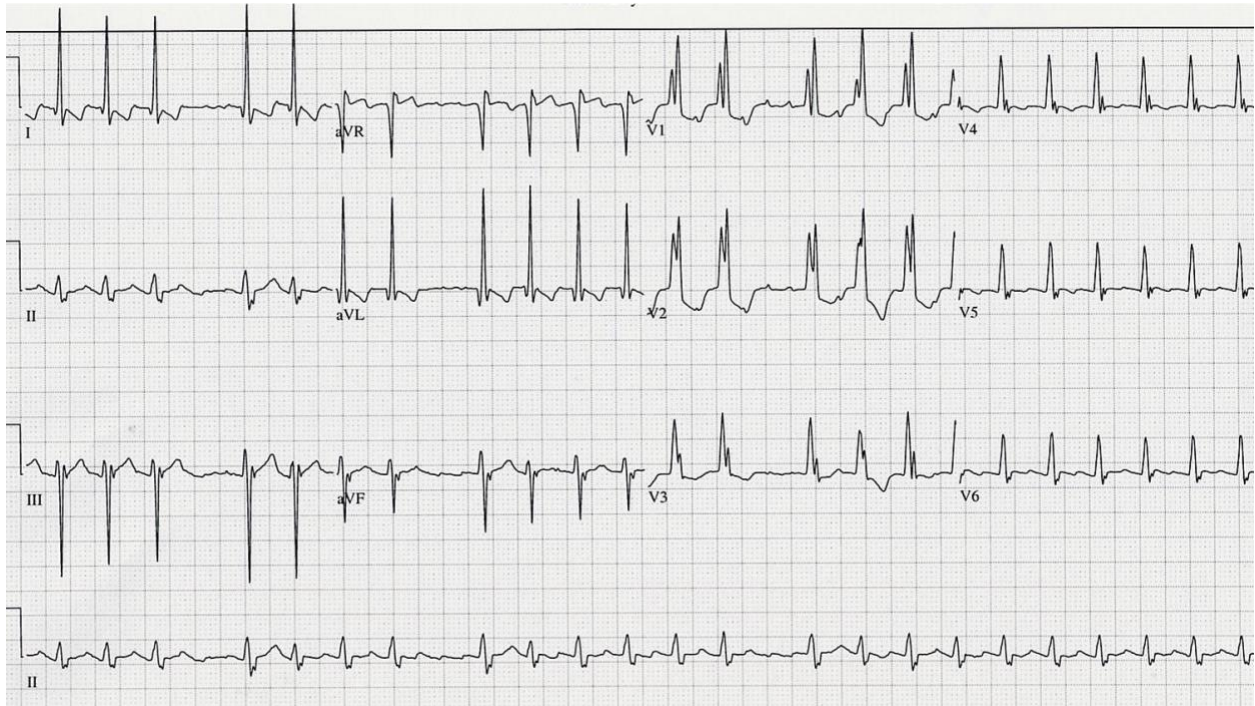
2. A 45 yo M presents with CP. His BP is 115/60. He is awake and alert.
What is the FULL ECG diagnosis?
(3 points)



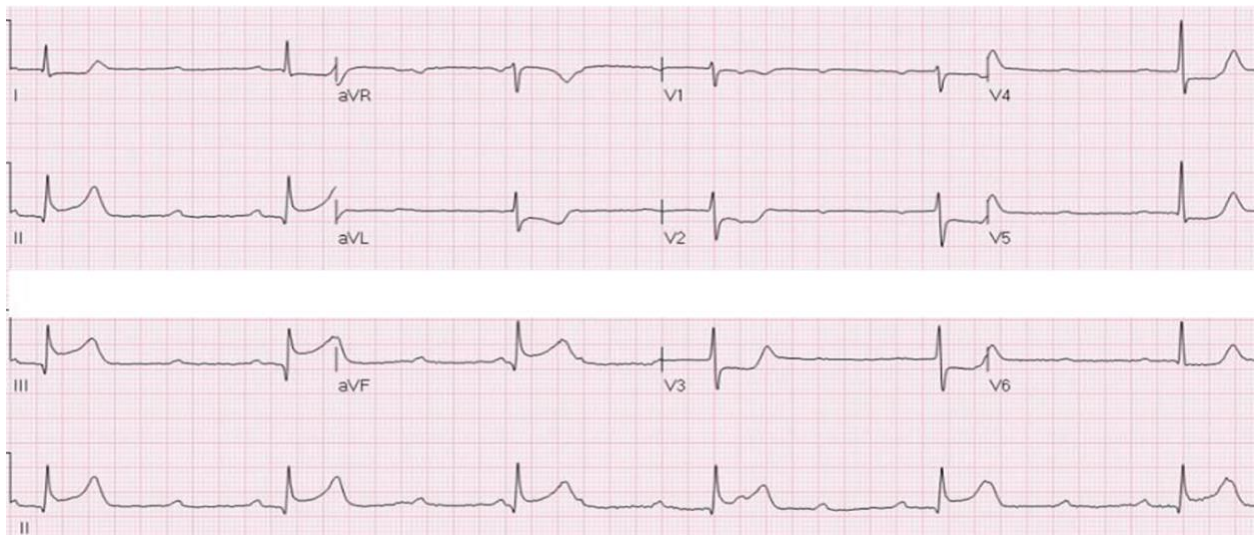
3. A 45 yo W presents complaining of palpitations. BP is 125/75.
What is the diagnosis?
Name 2 options for immediate management.
(4 points)



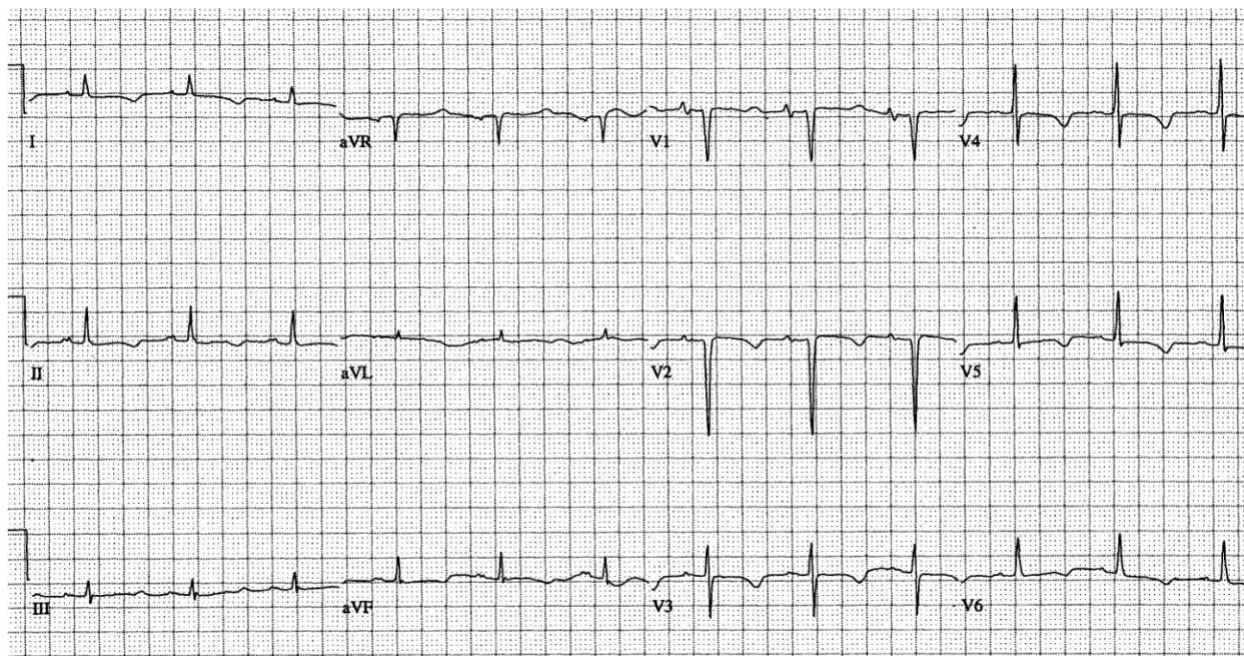
4. A 60 yo W presents with palpitations and dyspnea. The ECG is below. What is the FULL ECG diagnosis? (4 points)



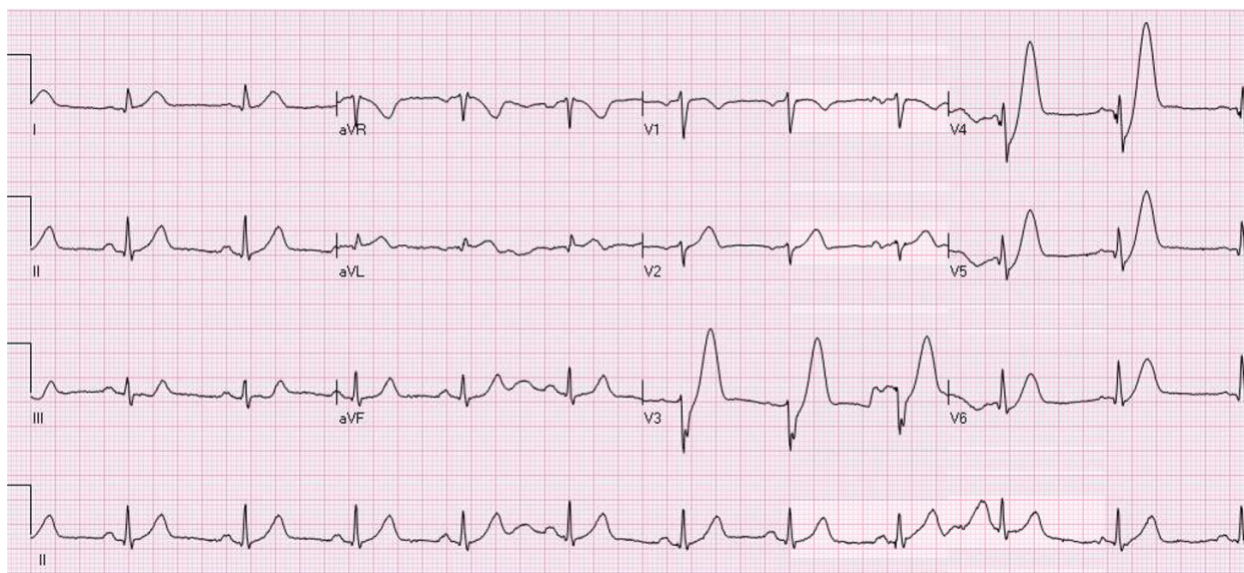
5. A 68 yo M with a history of CHF presents with CP and vomiting. What is the FULL ECG diagnosis? (4 points)



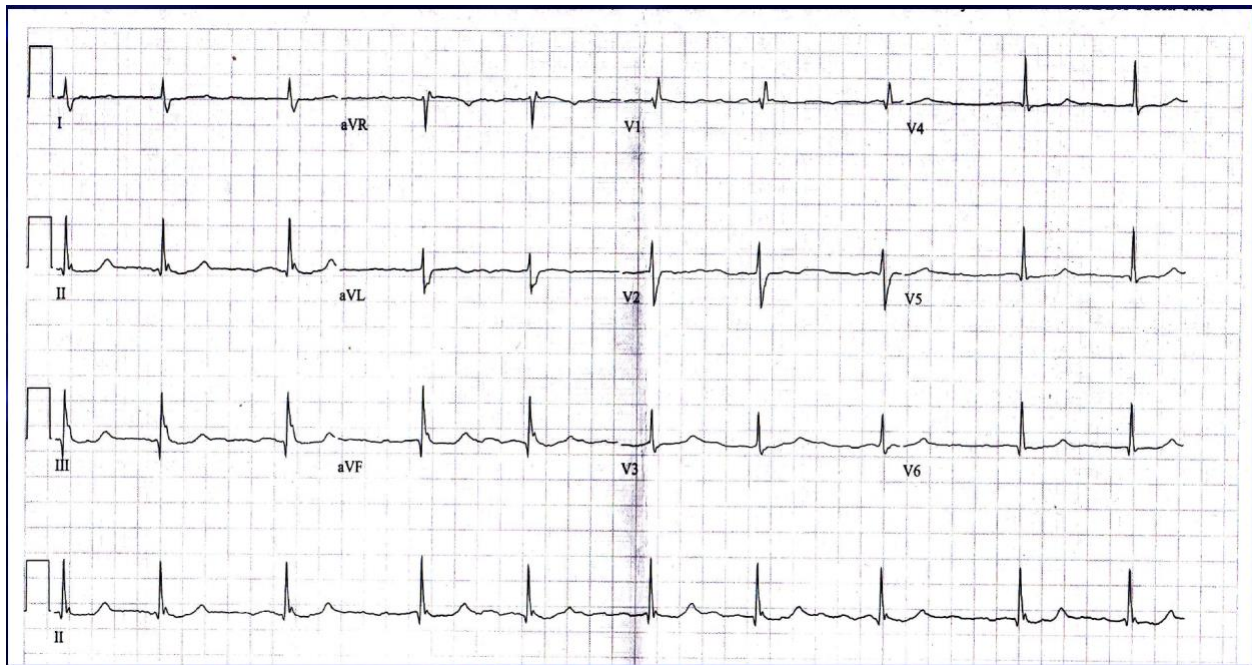
6. A 35 yo W presents with numerous episodes of palpitations and near-syncope. What is the likely cause of the palpitations/near-syncope, and give the FULL ECG diagnosis and treatment? (4 points)



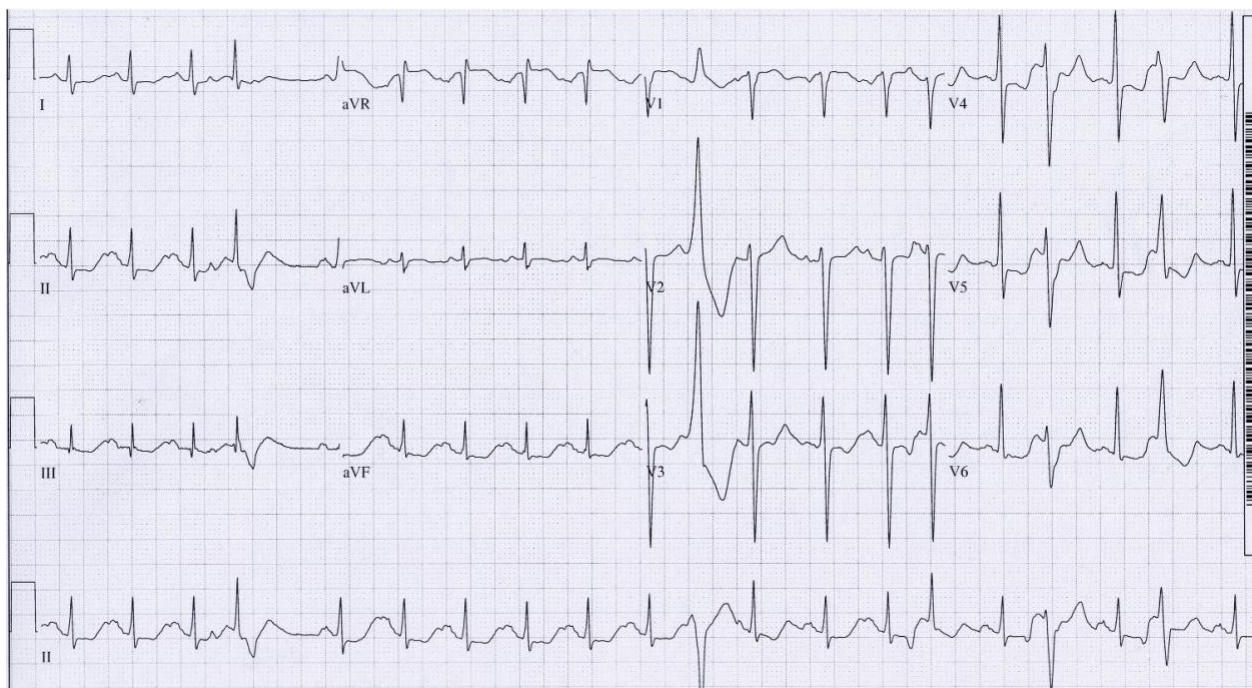
7. A 60 yo M presents with chest pain and dyspnea. His BP is 118/67. What is the ECG interpretation, the underlying cause of this, and the immediate treatment of choice? (4 points)



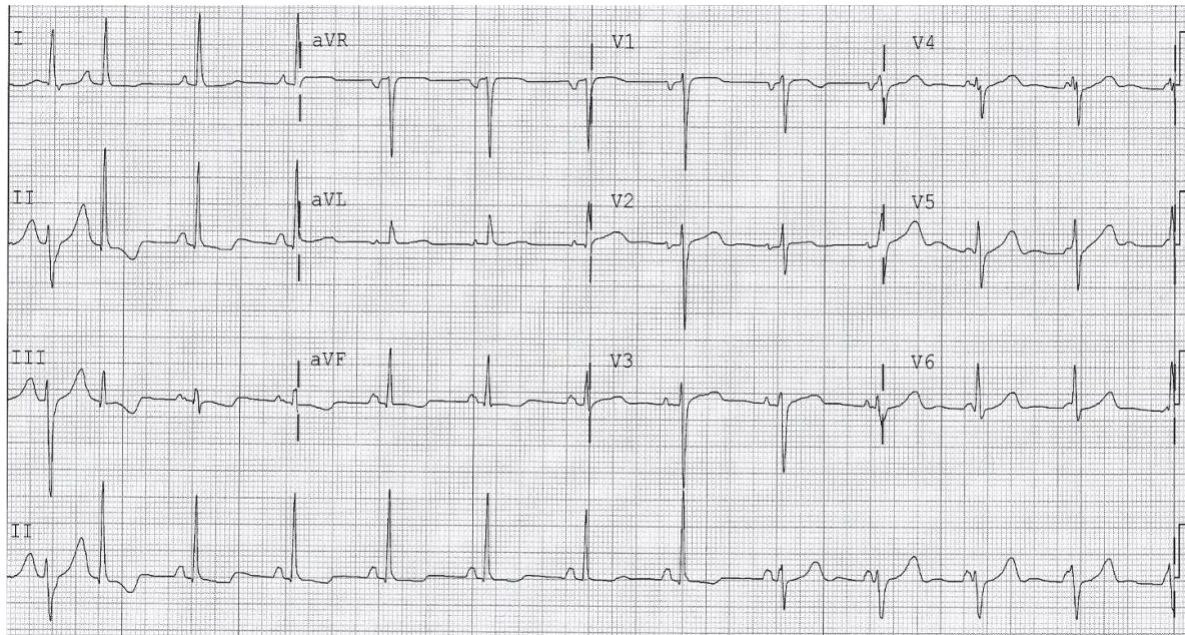
8. A 30 yo M presents with progressive fatigue, dyspnea on exertion, palpitations and recent syncope. What is the expected cardiopulmonary exam finding and the FULL ECG diagnosis? (4 points)



9. A 68 yo W presents with lightheadedness, nausea, and vomiting. The following ECG is obtained. What is the FULL ECG diagnosis and treatment? (4 points)



10. A 43 yo M presents with a palpitations. His ECG is below. What is the FULL ECG diagnosis?
(4 points)



11. 35 yo W presents with palpitations after a syncopal episode earlier in the day. What is the FULL ECG diagnosis? (4 points)

