

13th Annual UMEM Residency ECG Competition

May 7, 2025



Name: _____

What program are you in? (circle one)

EM

EM/Peds

EM/IM

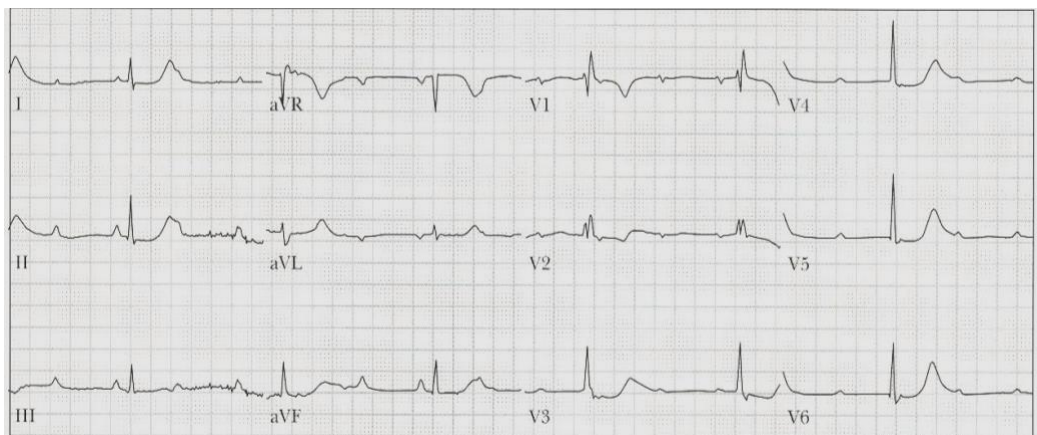
EM/IM/CC

What is your PG year? (1-5) _____

PLEASE READ THIS PAGE BEFORE BEGINNING!

In some of the following questions, I'll ask you for a FULL ECG interpretation/diagnosis. Here's what I am asking for:

SAMPLE QUESTION: A 58 yo M presents with chest pain and the ECG noted below.
What is the FULL ECG diagnosis? (5 points)



Answer:

Sinus tachycardia, complete heart block, junctional escape rhythm, RBBB, diffuse ischemia

In this example, I would give you 1 point for identifying the atrial rhythm (ST), one point for identifying CHB, 1 point for identifying that there is a junctional escape, 1 point for identifying the RBBB, and one point for noting the ischemia (ST depression in multiple leads). In other words...

be complete in your interpretation!

Be sure that you don't just *describe* what you see....*interpret* the ECG! For example, I don't want you to say "ST depression in ___ leads." I want you to say "diffuse ischemia."

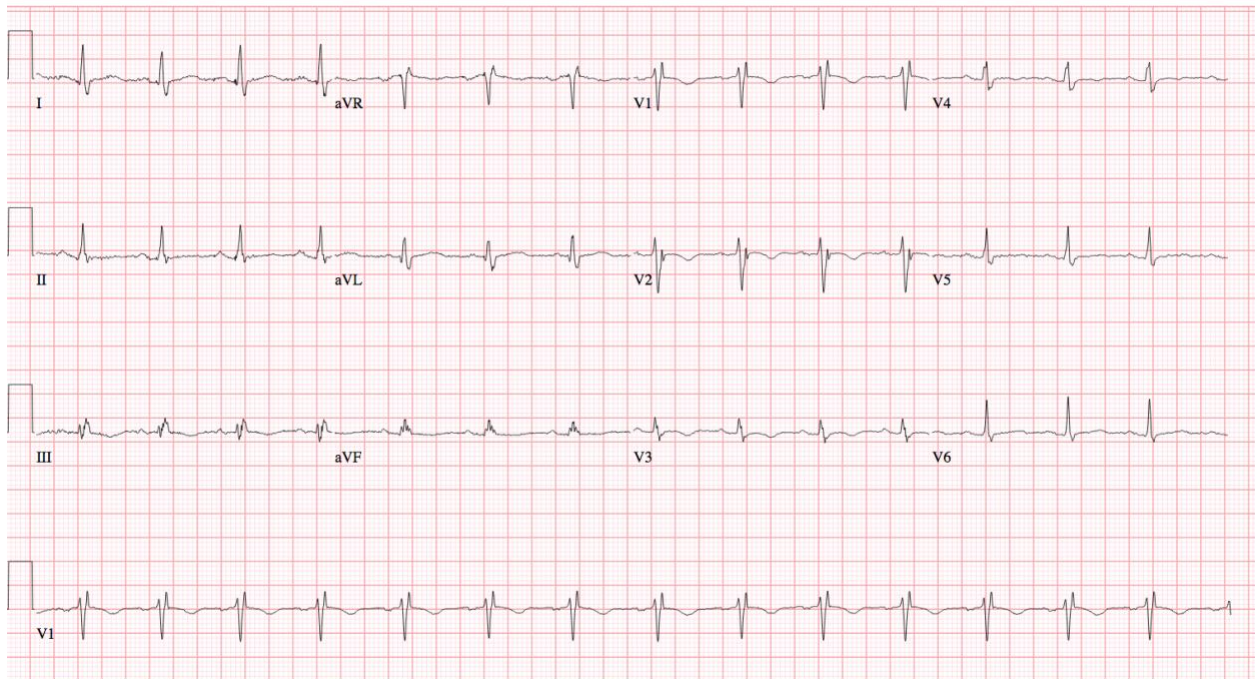
Also, in your interpretation, if you think there's an underlying issue, say it.

For example, if you think the underlying dx is hyperK, or TCA OD, or Brugada, etc., say it.

Don't assume that points correlate with the number of things I am looking for. For example, if something is worth 3 points, that does NOT mean there are 3 things you need to list! Points are allotted based on how important I think something is.

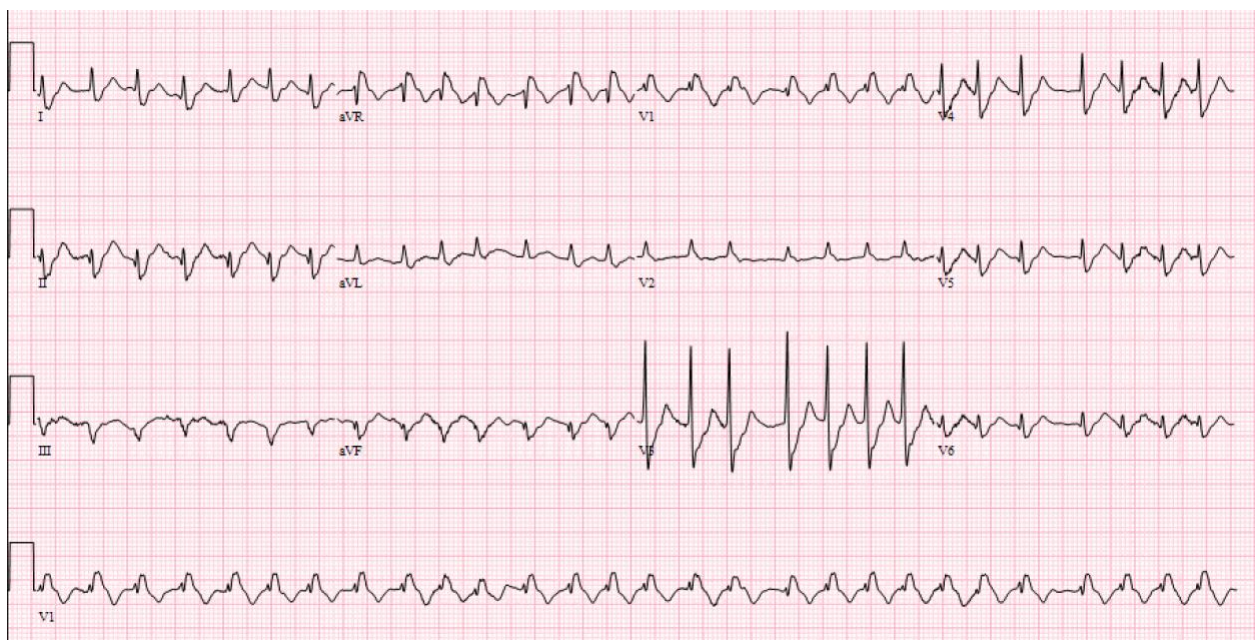
1. A 36 yo W presents after an episode of palpitations and near-syncope. Her BP is 115/60. She is awake and alert.

What is the FULL ECG diagnosis? (3 points)

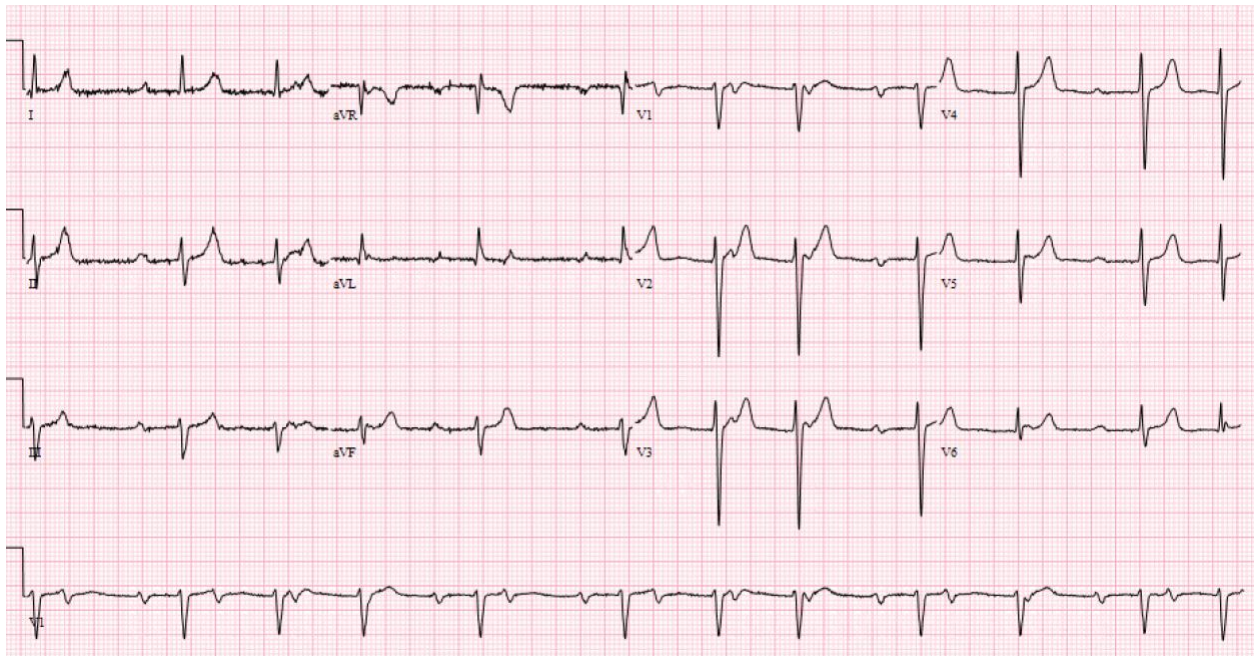


2. A 75 yo M presents complaining of palpitations. BP is 125/75.

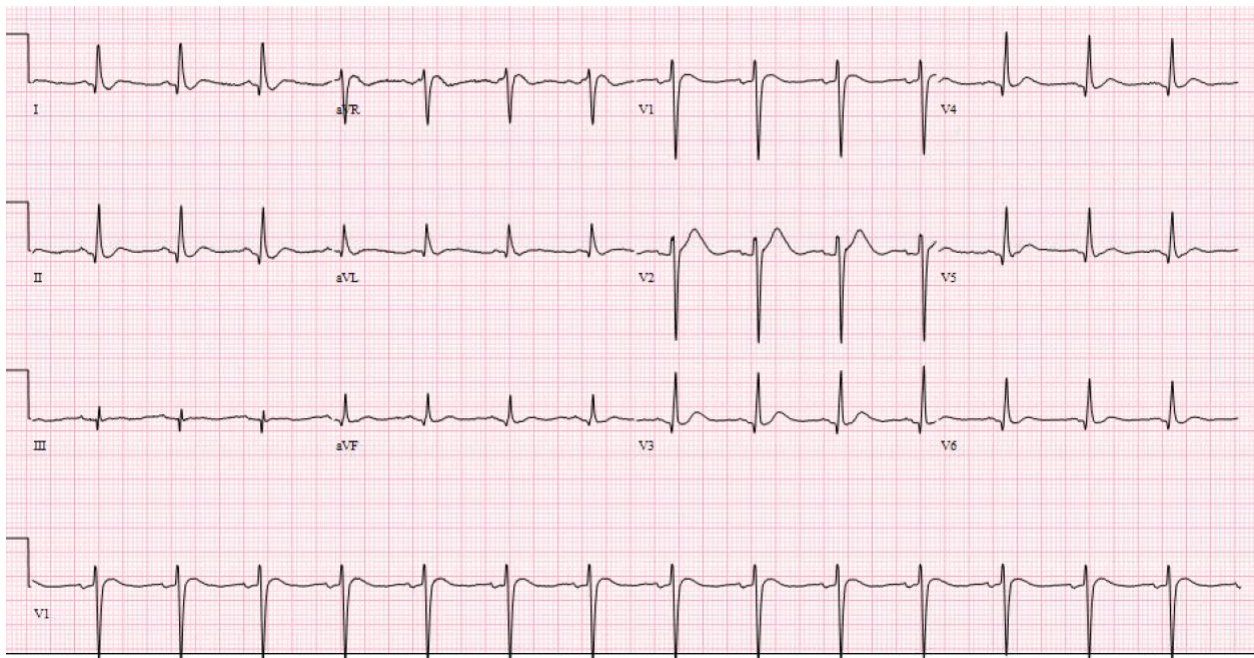
What is the FULL ECG diagnosis? (3 points)



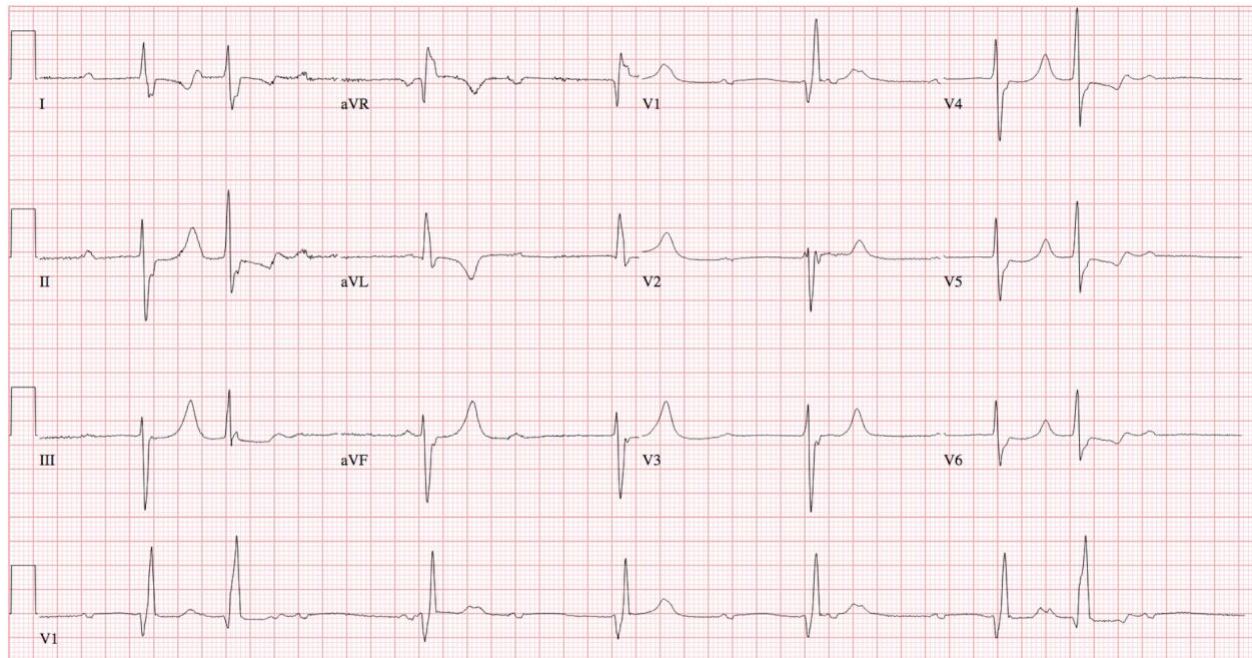
3. A 74 yo M presents with weakness. His BP is 82/50.
 What is the FULL ECG diagnosis? (2 points)
 What is the best initial treatment? (2 points)



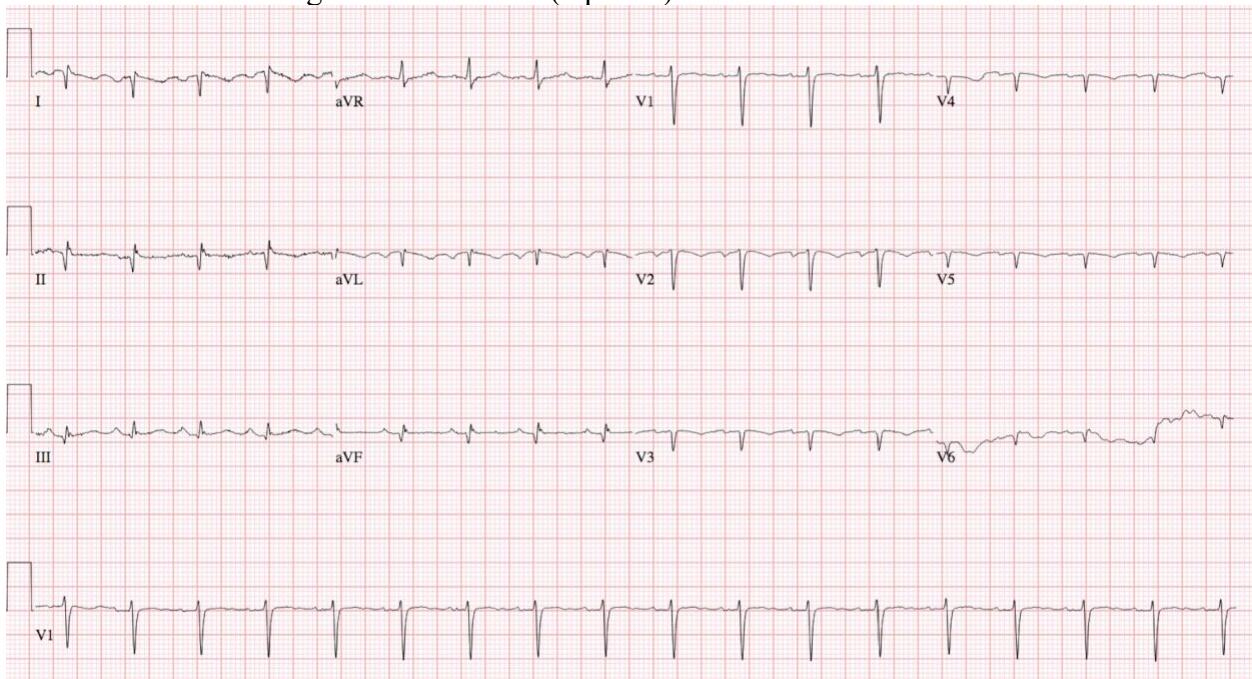
4. A 67 yo W presents with severe malaise and confusion. BP is 115/50.
 What is the FULL ECG diagnosis? (2 points)



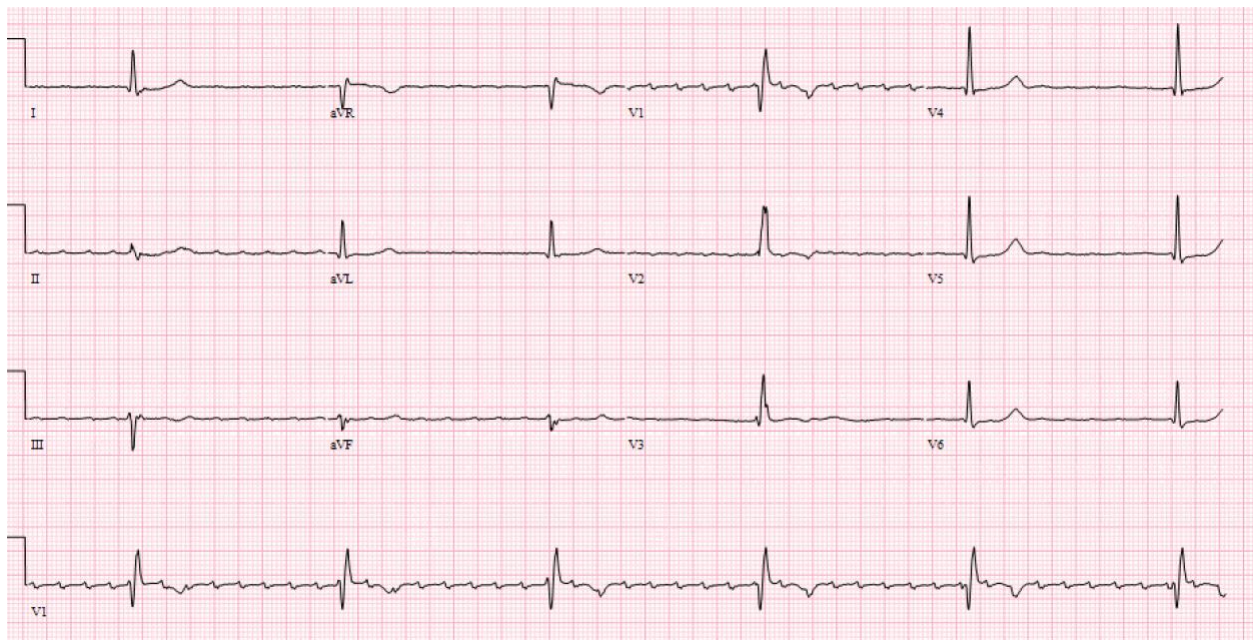
5. A 54 yo M presents with episodes of palpitations and near-syncope.
What is the FULL ECG diagnosis? (5 points)



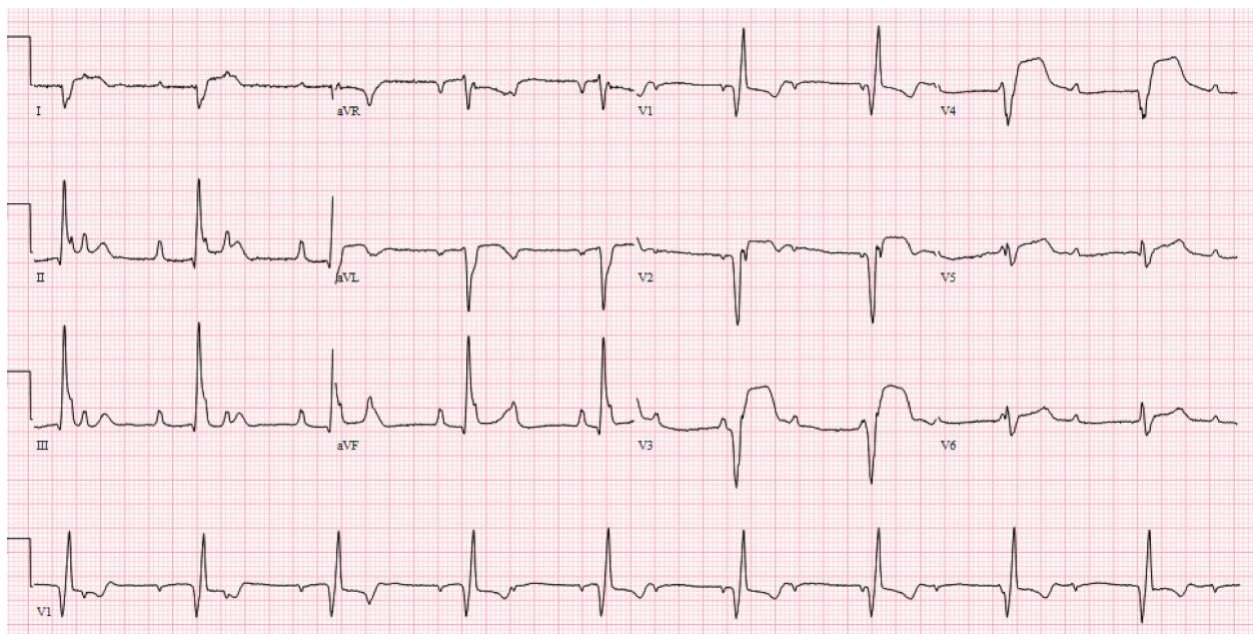
6. A 42 yo W presents with dyspnea. Her BP is 118/67.
What is the FULL ECG diagnosis? (2 points)
List 6 other causes of right axis deviation. (3 points)



7. A 92 yo M presents with lightheadedness and dyspnea. BP is 85/55.
 What is the FULL ECG diagnosis? (3 points)
 What is the best immediate treatment? (2 points)



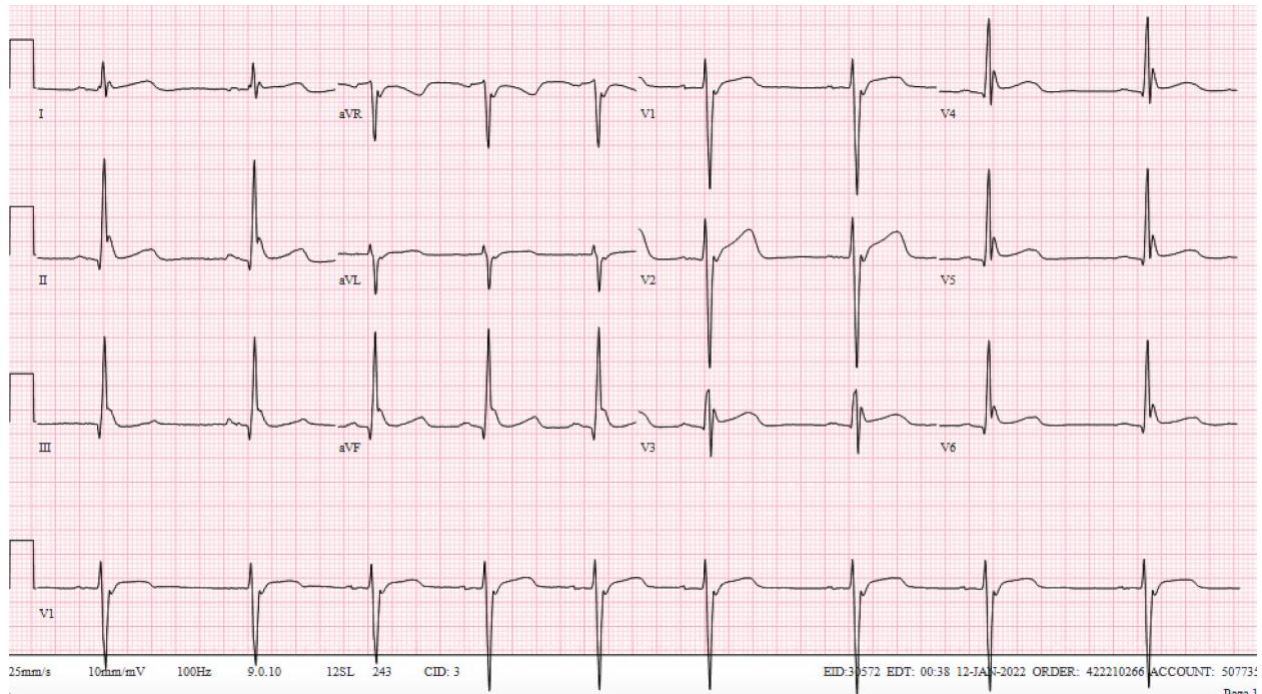
8. A 87 yo M presents with chest pain, nausea, and vomiting. BP is 110/65.
 What is the FULL ECG diagnosis? (6 points)



9. 26 yo W presents unresponsive. BP 85/45.

What is the FULL ECG diagnosis? (2 points)

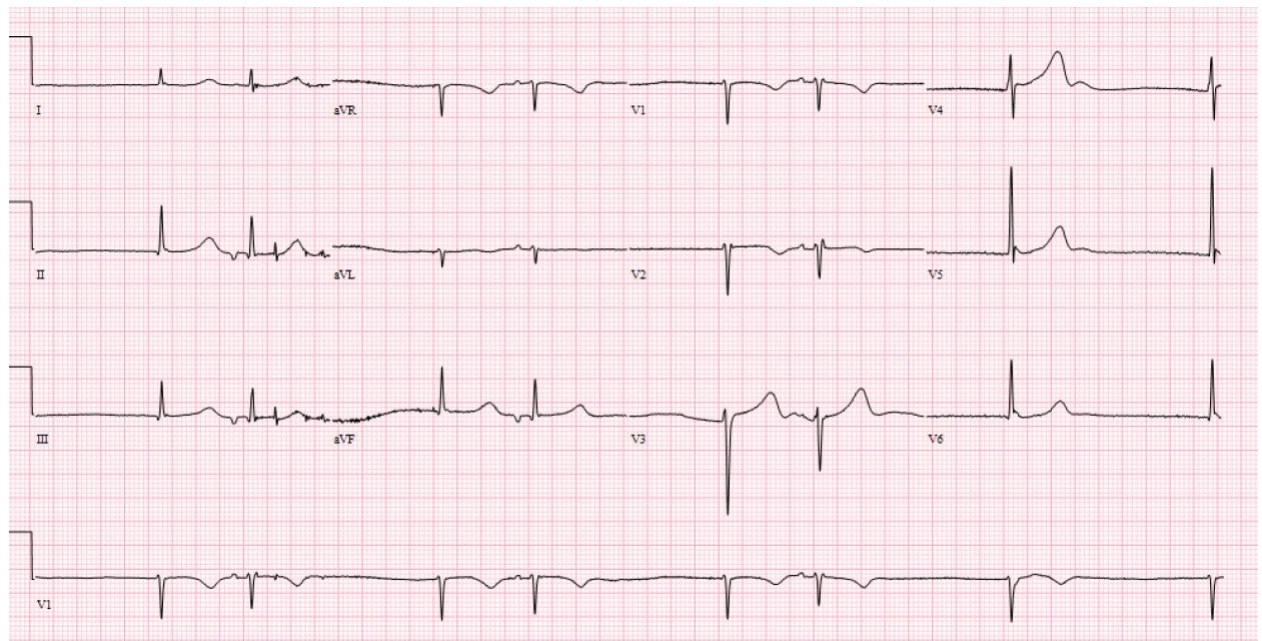
List 4 ECG findings often associated with this condition. (2 points)



Bonus ECG case 10. A 69 yo M presents with lightheadedness.

What is the FULL ECG diagnosis?

(3 points)



11. What is the Bix rule? (2 points)

12. What is Ashman phenomenon? (2 points)

13. Describe (or draw) what de Winter T waves are, in which leads you find them, and what they predict in the cath lab. (3 points)

14. Describe the Aslanger pattern and what it predicts in the cath lab. (3 points)